



Plant Archives

Journal homepage: <http://www.plantarchives.org>
doi link : <https://doi.org/10.51470/PLANTARCHIVES.2021.v21.S1.305>

STUDY OF DEVELOPMENTAL MORPHOHISTOGENESIS OF LOWER RESPIRATORY SYSTEM IN SHEEP BY LIGHT MICROSCOPY

Hassan R. Ghazi* and Jafar G. Abbas Al-Jebory

Department of pathology, Veterinary Medicine Collage, Al-Qasim Green University, Iraq

*Email: hassan.rajih@yahoo.com

ABSTRACT

The present work was designed to investigate the developmental morphohistogenesis features of the lower respiratory system lung in sheep project was carried out in the College of veterinary medicine / AL-Qasim Green University to study and determine the time of formation and appearance of different structures of the lower respiratory system. The study was performed on twelve sheep fetuses that are collected from healthy pregnant ewes slaughtered in the abattoirs of Baghdad, Najaf, and Babylon provinces for prenatal study and twenty-four animals in different ages postnatal (1week, 1month, 2month, 6month, 3years, 4years). The sheep fetuses at prenatal stages are distributed into three groups: (first, second and third trimester) according to the gestational age which is determined depending on the crown-rump length (CRL) While, the samples at the postnatal stage are distributed into six groups (neonate: at one day age, neonate: at one month age, lamb: at two months age, lamb: at six months age, adult: at two years age and aged: at four years ago). Routine histological stain (H&E) and periodic acid shift (PAS), Masson's trichrome stain (MISSION) in addition to a scanning electron microscope (SEM) were conducted to get current aims. The study revealed that the differentiation and development of the lower respiratory system began in the sheep embryo between thirteenth to one-hander twenty days of pregnancy as a respiratory diverticulum, where the tracheal bud begins at the first trimester of gestation, while the anlage of the lung appears at the third trimester of pregnancy, all previous events occur during the organogenesis stage and body systems formation which includes respiratory system and its appendixes. Tracheal development in sheep appears in the second trimester of gestation compose of the twelfth day of gestation, as a longitudinal diverticulum of endodermal epithelium that evaginates from the floor of the pharynx and tubular foregut while tracheal cartilage differentiated at the fourteenth of gestation and observation at the sixteenth day of gestation. The evolution and differentiation of the lung undergoing a series of histomorphological changes in embryonic life and continued until after birth and it's passed through different complex and sequential morphological changes represented by the following stages: embryonic stage, pseudo glandular stage, canaliculi stage, saccular stage, and alveolar stage. After the end of the embryonic period, the embryo was completed portion from its development and divisions especially lung to born and goes out from the mother uterus after the nineteenth or twentieth day to continue with growth to the lung that not it's mature completely. The present study demonstrates that the sheep lung at birth shows not well developed and immature with the continuous formation of new alveoli up to about eight weeks of age after birth. Between thirteen and sixteen-day old sheep pups, the lung becomes completely mature when noticed lung histologically containing all histological picture which found in the adult lung as lobar bronchi, segmental bronchi, bronchioles, terminal bronchioles then directly alveolar duct, alveolar sac, respiratory alveoli, pneumocystis type I, II and all composition of the lung. The aimed to provide a more complete quantities description of the Histomorphological developmental of the lower respiratory system (lung and trachea).and Detection the timing of first appearance of the components of the lung at intrauterine life and complication it is development after birth with determine teratogenic effect to some drugs and pollutions during comparative studies with normal development and finally make as basic extrapolation for other comparative studies. This study was designed to describe the morphological and histological features of lung at prenatal and postnatal stages with determine the changes which accrue during this stages. A samples are collected in period between (October to January) of years (2019-2020). The study is performed on twelve sheep fetuses that are collected from healthy pregnant ewes slaughtered in the abattoirs of Baghdad, Najaf and Babylon provinces for prenatal study and twenty-four animals in different ages for postnatal study. The results showed that the lung of sheep fetus in current stage located in saccular stage level and the period between the pervious and current stage represent gradual morphological alteration of fetus lung from canalicular to saccular stage.

Keywords: lower respiratory system, light microscopic, sheep

Introduction

Sheep are an important source of meat and wool production and also share a good proportion of milk production. Iraqi sheep are coarse wool, accounting for 72-75% of the total livestock in Iraq (Abdul Karim *et al.*, 1980). Sheep in Iraq are distributed in five breeds (Hamdani, Karadi, Arabi, Naeimi, and Awasi). Which consider very important economic ruminants for different production. Awassi sheep (*Ovis aries*) a species spreading mainly in the middle of Iraq belong to the family Bovidae, subfamily Caprine, Genus ovis. There are several species of local sheep

in Iraq, such as awassi sheep, which is found in the Euphrates, southern and northern region, and the Kurdish and Hamdani sheep in the northern regions, and the Arab sheep in the south-eastern region of Iraq. There is a biological ape, its gas exchange during inhalation and exhalation, consist of several organs. The function of the respiratory is to transfer carbon dioxide oxygen between the lung and tissues. in all the vertebrates, respiration process is done by the lungs (Akers and Denbow, 2013)". Sheep resistance against respiratory diseases is weak, and most cases that lead to death in sheep in pulmonary infections such as Pasteurella (microbial infection), and when there is a respiratory

symptom in the herd, the number of infected animals is taken into account, and whether infected animals were introduced to the herd, and the design of sheds: their division and direction. Have animals been immunized against respiratory diseases. the most important respiratory disease is pulmonary infections in lambs, a common disease that occurs, ranging from acute fatal condition (sudden death) without symptoms; to a chronic condition, characterized by high temperature and tightness in tuna Vas, cough, purulent runny nose, and lacrimal secretions, then prolapse and mortality. The death rate may reach 30% of infected lambs before weaning, and this disease is prevented by avoiding exposure to high or very cold temperatures for lambs or overcrowding in poorly ventilated sheds or malnutrition. Anatomically, the respiratory system consists of two parts: firstly, the upper respiratory tract is included in the nose, nasal cavity, pharynx, and larynx. The lower respiratory tract is included the trachea, bronchi, and lungs (Dudek, 2014). Initially, upperparts develop when the nasal placodes appear (ectodermal thickenings) become nasal pits by developing of the surrounding lateral and medial nasal processes; along with transforms the pits into a nasal cavity, follow that to the left and the right medial nasal processes to forming a primary palate (upper lip and incisive bone) and a nasal septum. The lateral nasal processes develop to lacrimal bones, nasal, and nose cartilage. Dividing of the secondary palate the nasal oral cavity into the three cavities (oral cavity, left and right of the nasal cavities) (Dudek, 2014). Bounded of the pharynx by pharyngeal arches externally; the arches are cover by pharyngeal clefts externally and by pharyngeal pouches internally. The pharynx is closed by the oropharyngeal membrane anteriorly that consists of surface ectoderm and pharyngeal endoderm); then the growth of the mouth (stomodeum), the oropharyngeal membrane should degenerate for communication (Fletcher and Weber, 2013). The lower respiratory system develops when originates as an invagination from the endoderm. Determination of the laryngotracheal groove depending on lateral walls of the laryngotracheal groove, while the ridges grow in the med, emerge along the midline to form the tracheoesophageal septum. Wherever, The septum separates a laryngotracheal tube (lung buds and future trachea) from the esophagus (Hyttel *et al.*, 2009; Sadler, 2015). The study was designed to provide a more complete quantities description of the Histomorphological development of the lower respiratory system (lung and trachea). And detection of the timing of the first appearance of the components of the lung at intrauterine life and complication it is developed after birth with determine the teratogenic effect on some drugs and pollutions during comparative studies with normal development and finally make as basic extrapolation for other comparative studies.

Materials and Methods

Anatomical study

Morphological study in prenatal stages

Morphological description of lung during intrauterine life including:

1. Position of lung and trachea.
2. Shape of lung and trachea.
3. Color of lung and trachea.
4. Lobulation of lung.

Macro morphometric measurements:

After collection of the fetuses, were utilized to study and record the following gross parameters in prenatal stages:-

A. Measurements of the crown-rump length (CRL) of all fetuses in different age.

B. Measurements of the weight of fetuses in different ages by using electronic sensitive balance.

C. Measurements of weight and dimensions of the lung in different age by using electronic sensitive balance.

D. Measurement Volume of lung by water displacement method.

Histological Study by Light Microscope:

Fetuses and pups in different stage were used after euthanasia and the common carotid artery was opened until death of the animals, then removal of the trachea and lung from the thoracic cavity immediately. The sample was taken as soon as possible from all lobes of both lungs (cranial, middle, caudal and accessory) lobes, from trachea (cranial, middle and caudal parts). These sample were fixed in 10% formalin and the solution must be 1:10 of the size of specimen and left for 48 hours (Suvana *et al.*, 2018). After fixation, the tissue was trimmed and the specimens were washed by tap water for 4-6 hours to remove the formalin solution then the steps:

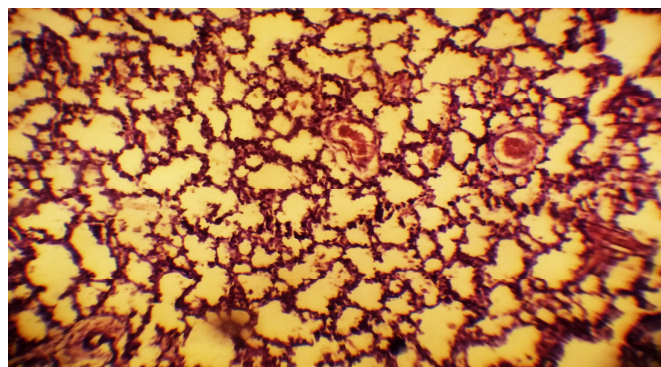


Fig. 1: Show the Caudal Lobe of lung, 110-120 days prenatal: Well-formed alveolar spaces and bronchial wall tissue. H&E. x100

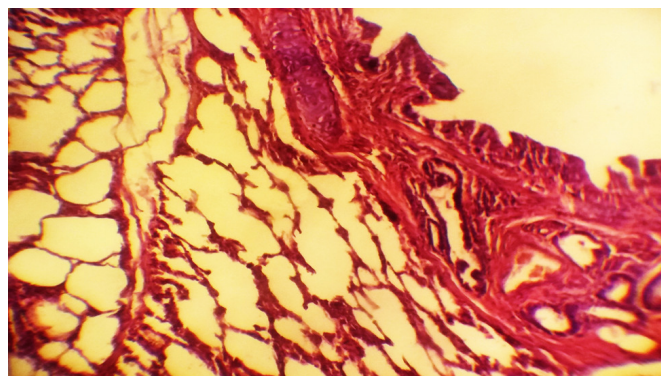


Fig. 2: Show the Lung, 30-40 days prenatal: Well-formed alveolar spaces, some are collapsed, with well-formed bronchial wall tissue. H&E. x100

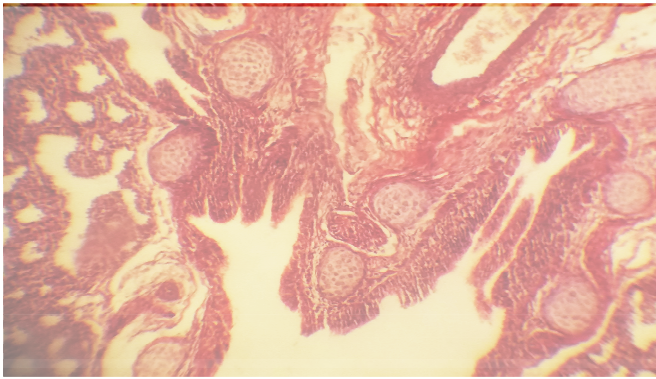


Fig. 3: Show the Lung, 80-90 Prenatal: Well-formed alveolar spaces, some are collapsed, with well-formed bronchial wall tissue. Methylene-Trichrome. X100.

2. Results

Crown-rump length of fetuses in prenatal stage:

Histogram (1) shows the relationship between the crown-rump length of embryo and the time of pregnancy. In the present study it is noticed that the curve of histogram increases gradually during the different periods of pregnancy and these elucidate the gradually increasing in size of embryo with sequential developmental stages during intrauterine life and this is in agreement with (Evans and Sack, 1973; Noakes, 2009).

Weight of fetuses in prenatal stage:

Fig. (4) shows the relationship between the weight of embryo and the time of pregnancy. The present study reveals that the curve of histogram increases very gradually at the days of pregnancy which represent the time of organogenesis sheep embryos, and this is similar to Klaassen (2001). These means that weight increases in embryos during organogenesis period is limited, while in differentiation stage will be high, and these are in agreement with (Miller *et al.*, 1993; Noakes, 2009); Robertson and Falconer, 1980) using sheep fetuses and (Kudu and Kaikini, 1987) in goat.

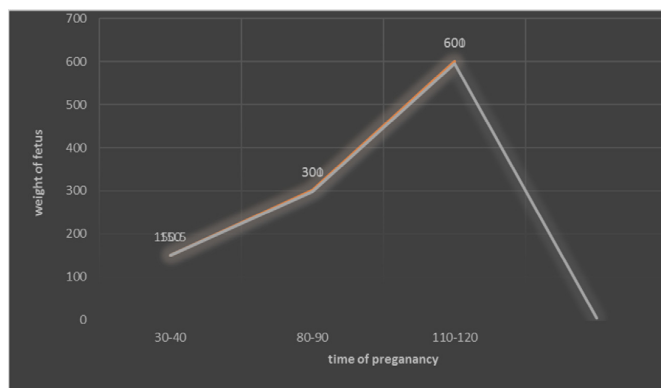


Fig. 4 : shows the relationship between the weight of embryo and the time of pregnancy.

Discussion

During this stage, there was a rapid proliferation of the primitive airways and the tubular branching of the lung airways continues to forms segmental and subsegmental bronchi with distinct lung lobes. The results showed present lung consist of left lobe, right cranial lobe, right caudal lobe, middle lobe and first anlage of accessory lobe. In this stage, the lung has distinctly glandular appearance therefore called pseudo glandular is derived from the histological appearance

of the lung which on cross section consists of hollow tubular-like structures (glands) surrounded by clusters of mesenchymal cells with development of pleural cavities.

This is the same finding (Knosp, 2002) while in human, the lung appear at pseudo glandular stage at (5-17) week of gestation; and in cat located between 23-25 days of gestation and in rat between 13-18 day of gestation but in rabbit occur at 18 day of gestation according to (Schittny and Burri, 2008)

During pseudo glandular stage, the airway tubes are proximally lined by tall columnar epithelium. The height of the cells decreases continuously toward the periphery, to reach a cuboidal shape in the terminal branches. The epithelium of the terminal buds maintain their cuboidal undifferentiated state until branching is completed. Denser mesenchyme surrounds the tubular sprouts characterized by a loose arrangement of mesenchymal cells immediately below the pleura called first zone, while in the second zone, the epithelial tubes are enwrapped by a more densely packed network of interstitial cells. The region between first and second zone is the sites of formation, growth and differentiation of the gas exchange region. The future conducting airways are located in third zone, which is characterized by epithelial tubes with an outer layer of smooth muscle cell precursors. In human, at the pseudo glandular stage progresses the early pseudostratified epithelium is gradually replaced by columnar cells proximally and distally by cuboidal cells which it rich with glycogen and all pre-acinar structures, including, pulmonary arteries and veins, pre-acin

Conflict of interest

No potential conflict of interest relevant to this article was reported.

Acknowledgement

We thanks all friends and the staff of veterinary collage, Al-Qasim Green University those help me to complete this study.

References

- Akers, R.M. and Denbow, D.M. (2013). *Anatomy and physiology of domestic animals*, John Wiley and Sons.
- Croy, B.A.; Yamada, A.T.; DeMayo, F.J. and Adamson, S.L. (2013). *The guide to investigation of mouse pregnancy*, Academic Press.
- Dudek, R.W. (2014). *BRS embryology*. 6th edition ed.: Wolters Kluwer Health.
- Evans, H. and Sack, W.O. (1973). Prenatal development of domestic and laboratory mammals: growth curves, external features and selected references. *Anatomia, Histologia, Embryologia*, 2(1): 11-45.
- Field, A. (2013). *Discovering statistics using IBM SPSS statistics*, Sage.
- Fletcher, T.F. and Weber, A.F. (2009). *Veterinary developmental anatomy. Veterinary Embryology (class notes)*: 36-39.
- Fletcher, T.F. and Weber, A.F. (2013). *Veterinary Developmental Anatomy (Veterinary Embryology)*. *University of Minnesota, EUA*: 38-41.

- Hyttel, P.; Sinowatz, F.; Vejlsted, M. and Betteridge, K. (2009). *Essentials of Domestic Animal Embryology* E-Book, Elsevier Health Sciences: 1-24.
- Kashi, A.M.; Tahemanesh, K.; Chaichian, S.; Joghataei, M.T.; Moradi, F.; Tavangar, S.M.; Najafabadi, A.S.M.; Lotfibakhshaiesh, N.; Beyranvand, S.P. and Anvari-Yazdi, A.F. (2014). How to prepare biological samples and live tissues for scanning electron microscopy (SEM). *Galen Medical Journal*, 3(2): 63-80.
- Noden, D.M. and Lahunta, A.d. (1985). *The embryology of domestic animals. Developmental mechanisms and malformations*, Williams and Wilkins.
- Rossant, J. and Tam, P.T. (2002). *Mouse development: patterning, morphogenesis, and organogenesis*, Gulf Professional Publishing.
- Sadler, T.W. (2015). *Langman's medical embryology*, Wolters Kluwer Health: 218-224.
- Suarez, C.J.; Dintzis, S.M. and Frevert, C.W. (2012). *Respiratory*. In Sundberg, J.; Nanne, L.; Fleckman, P.; Treuting, P. and Dintzis, S. (Eds.), *Comparative Anatomy and Histology: A Mouse and Human Atlas* (Pp: 121-134.). Amsterdam: Elsevier.
- Suvarna, K.S.; Layton, C. and Bancroft, J.D. (2012). *Bancroft's Theory and Practice of Histological Techniques* E-Book, Elsevier Health Sciences.